

PATHOLOGICAL CHANGES WHICH THELOHANELLUS NIKOLSKII CAUSE ON THE FINS, SCALES AND SKIN OF COMMON CARP

NIKOLINA NOVAKOV¹, MIROSLAV ĆIRKOVIĆ¹, DRAGANA LJUBOJEVIĆ¹,
RADOVAN BABIĆ², NEVENKA ALEKSIĆ³

¹University of Novi Sad, Faculty of Agriculture, Trg Dositeja Obradovića 8, 21000
Novi Sad, Serbia; e-mail: milosevicnina@gmail.com

²Veterinary institute of the Republic of Srpska, „Dr Vaso Butozan“, Branka Radičevića
18, 78000 Banja Luka, Republic of Srpska, Bosnia and Hercegovina

³University of Belgrade, Faculty of veterinary medicine, Bulevar Oslobođenja 18,
11000 Belgrade, Serbia

PATOLOŠKE PROMENE NA PERAJIMA, KRLJUŠTIMA I KOŽI ŠARANA IZAZVANE THELOHANELLUS NIKOLSKII

Apstrakt

Telohaneloza je obolenje koje se javlja kod svih kategorija šarana. Uzročnik je protozoa *Thelohanellus nikolskii*. Manifestuje se u dva oblika. Prvi se javlja kao telohaneloza na perajima kod jednogodišnjih mladunaca šarana, a drugi kao telohaneloza krljušti i kože kod dvogodišnjih, trogodišnjih i višegodišnjih kategorija ribnjačkog šarana (*Cyprinus carpio*). Istraživanjima koja su trajala u periodu od 2008-2012. godine obuhvaćeno je 22 ribnjaka, od čega se 18 nalaze u Srbiji a 4 u BIH, Republika Srpska. Praćenjem epizootiološke rasprostranjenosti utvrđeno je da su oba oblika oboljenja bila prisutna na svim ispitivanim ribnjacima. Kod telohaneloze krljušti prevalenca se kretala od 2-75% a intenzitet infekcije 2-206 cisti po jedinki, dok su iste vrednosti kod telohaneloze na perajima iznosile 3-30%, odnosno 2-84 ciste. Promene na krljuštima bile su prisutne tokom aprila i maja, a na perajima tokom jula i avgusta. Tokom epizootiološkog praćenja i istraživanja promena na krljuštima zapaženo je da na njima dolazi do formiranja cisti okruglastog oblika koje su dostizale veličinu i do 3 mm. Promene na krljuštima zabeležene su kod dvogodišnjih mladunaca koji su najčešće bili inficirani, ali i kod trogodišnjih i četvorogodišnjih konzumnih i matičnih kategorija šarana, dok kod jednogodišnje mlađi nisu ustanovljene ni u jednom slučaju. Ciste su bile prisutne kako kod mnogoljuskavih šarana, koji su potpuno prekriveni krljuštima, tako i kod maloljuskavih gde su se promene nalazile na dorzalnom redu krljušti. Takođe je uočena i pojava cisti na koži, a ne i na krljušti kod četvorogodišnjih matičnih riba. Tokom čitavog

vegetacionog perioda na perajima su primećivane malformacije i nedostaci dela peraja kod mladunaca. Jedinke kojima su otpala repna peraja postajale su plen ribojedih ptica. Najveći broj cisti nalazio se na repnom peraju, zatim na leđnom, grudnom, trbušnom i analnom. Merenjem i određivanjem morfoloških karakteristika spora izolovanih iz plazmodijuma sa krljušti dvogodišnjih mladunaca i plazmodijuma sa peraja jednogodišnje mlađi dobijene su vrednosti dužine i širine spora, kao i dužine i širine polarnih kapsula. Prilikom determinacije patohistoloških karakteristika utvrđena je struktura plazmodijuma, gde se u centralnim delovima nalaze sporame, dok se na periferiji nalaze razvojni stadijumi i pansporoblasti, te se na osnovu dominacije pojedinih ćelija unutar njega može utvrditi da li se radi o mladim ili o zrelim cistama. Plazmodijum se razvija unutar kalcifikovane kolagene kapsule, koja predstavlja tanak sloj kalcifikovanog kolagena oko kojeg se nalaze izdužene ćelije – skleroblasti, koji su zaduženi za formiranje ciste. Molekularnim tehnikama i BLAST analizom potvrđeno je da je etiološki uzročnik *Thelohanellus nikolskii* isti za oboljenje jednogodišnjih mladunaca na perajima i višegodišnjih šaranskih riba na krljuštima i koži. Značajan momenat širenja telohaneloze predstavlja promet mladunaca između ribnjaka gde se ne vodi računa o postojanju ove bolesti. Drugi bitan faktor je hidrografska povezanost ribnjaka, gde se ispuštanjem i upuštanjem vode omogućava prenošenje uzročnika bolesti. S obzirom na malu udaljenost ribnjaka ribojede ptice takođe predstavljaju bitan vektor širenja bolesti. Pošto ne postoji ni jedno adekvatno terapijsko sredstvo, kontrola telohaneloze i dalje se bazira na pridržavanju osnovnih sanitarno–profilaktičkih mera, kao što su isušivanje objekata, izmrzavanje, mehanička obrada tla i dezinfekcija krečom.

Ključne reči: *Thelohanellus nikolskii*, patološke promene, krljušt, peraje, *Cyprinus carpio*

Keywords: *Thelohanellus nikolskii*, pathological changes, scales, fin, *Cyprinus carpio*

INTRODUCTION

The myxosporidian *Thelohanellus nikolskii* was described for the first time by Achmerov (1955) from common carp living in river Amur. In Europe the parasite was first detected in Hungary more than 30 years ago (Jeney, 1979). In Serbia *Thelohanellus nikolskii* was present and reported since the beginning of the eighties (Ćirković et al., 1983). Wolf and Markiw (1984) were brought a turning point in developmental cycle of myxosporidia. They determined that an intermediate host is necessary for infection on *Myxobolus cerebralis* life cycle. The pathological changes and ultrastructure caused by *Thelohanellus nikolskii* present in the form of cysts on the fins of one year old carp fingerlings were studied by Molnar (1982), Desser et al. (1983) and Ćirković et al. (1997). Moshu and Molnar (1997) described for the first time *Thelohanellus* infection of the scales in the 2-4 years old European wild carp (*Cyprinus carpio carpio*). Ćirković et al. (2009) and Novakov (2013) have detected and described telohanellosis on the scales and skin in common carp (*Cyprinus carpio*) from Serbia. The aim of this paper is to describe pathological changes which *Thelohanellus nikolskii* causes on the fins, scales and skin of pond cultured common carp.

MATERIALS AND METHODS

The investigation was carried out from 2008 to 2012 on 18 fish farms in Serbia (Bač, Svilojevo, Kolut, Sombor, Srpski Miletić, Ruski Krstur, Susek, Despotovo, Bečej, Žabalj, Lukino Selo, Mošorin, Sečanj, Banatski Dvor, Novi Itebej, Jazovo, Novi Kneževac, Kanjiža) and 4 fish farms in Bosnia and Hercegovina (Prijedor, Prnjavor, Bardača, Brod). Fish material included 1- to 4 yr-old pond-cultured common carp (*Cyprinus carpio*). Sampling at the fish farms was conducted between April and October with the intervals of 7-14 days. During each visit of pond, clinical examinations were performed on a hundred of fish, and for laboratory examination complete parasitological dissection was performed on 21 specimens of common carp. Light microscopy examinations of fresh smears from different organs were conducted during dissection by compression between 2 slides to look for myxosporean parasites. The location of cysts was recorded. Measuring of fresh spores and capsules length and width was performed by using the software program Cell B. Pathohistological examination was conducted by standard techniques: following fixation with Bouin's solution, the tissue samples were processed, sliced to 5- μ m-thick sections, mounted and stained in haematoxylin and eosin. Photographs were taken in a Olympus BX51 microscope.

RESULTS AND DISCUSSION

During the five-year investigation, round cysts reaching 3 mm in diameter (Fig. 1) were found on scales of 2 to 4 year-old pond-cultured common carp. The cysts were located at the outer margin of scales. The cysts sizes were related to different stages of infection. They were significantly smaller at the beginning of infection than in the final stage, when reaching a maximum size. Plasmodia on scales were present from the beginning of April until the end of May, while characteristic changes were not observed during the rest of the year. In 2008, the cysts were observed on scales in Susek, Žabalj, Jazovo and Bač fish farms, while in the period of 2009-2012 scale changes were present in all investigated farms. The prevalence of infection ranged from 2 to 75%, while its intensity was 2 - 206 cysts per fish.



Figure 1. Cysts present on scales of two year old common carp fingerling

Changes on scales were found in two-year-old fingerlings that were the most often infected, but also in three-year and four-year old common carp individuals. Cysts were

not observed in one-year-old fry. The cysts were mainly present in carps, which were completely covered with scales, but also in mirror carps, where plasmodia were located in the dorsal row of scales. Also sporadic, cysts were detected on the skin of four-year-old spawn carp (Fig. 2)



Figure 2. Four year old spawn carp with cyst located on skin

Thelohanellosis on the fins was also present in all investigated fish farms. Cysts were noticed in the 60 days old carp fingerlings. The prevalence of infection ranged from 3 to 30 %, while its intensity was 2 -84 cysts per individual. Cysts were present in all fins (Fig. 3).



Figure 3. Cyst present on the common carp fins.

Plasmodia develop on scale's surface inside a calcified collagenic capsule (Fig. 4). Cartilaginous parts around the plasmodia break into pieces and calcified islets appear inside the connective tissue around the cyst (Fig. 4). The wall of the cysts around the plasmodium contains a thin layer of calcified collagen, as Moshu and Molnar (1997) called them elongated cyst-forming scleroblast cells. The central parts of plasmodia are filled with spores, while in the periphery vegetative developmental stages and pansporoblasts are present. Based on the dominance of individual cells within the plasmodium, it can be determined whether it is young or mature cysts.

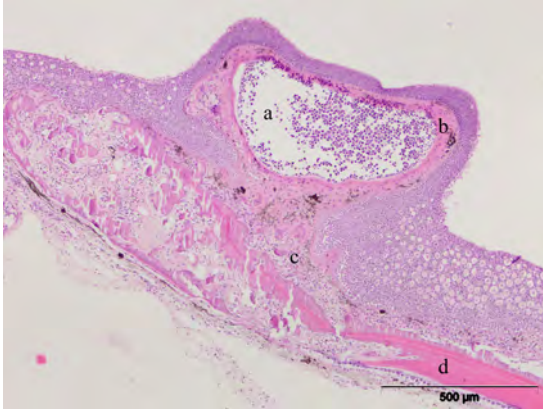


Figure 4. *Cyprinus carpio*. Cross section of scale with present plasmodium (a), cartilage of scale (b), calcified islets (c) and collagenic capsule (d). H&E

For measurements and morphological characteristics determination fresh spores were taken from plasmodia of scales and fins. Isolated spores were oval, with a large polar capsule in which turns of polar filaments can be detected. Measurement results of fresh spores and capsules length and width are shown in Table 1.

Table 1. Measurement values of spores isolated from scales and cysts.

Localization of spores	Spore length (μm)	Spore width (μm)	Capsule length (μm)	Capsule width (μm)
Scales	17,7 (13.5-20.3)	10,9 (10-12.1)	7,1 (6.1-8.7)	6,2 (5.8-6.6)
Fins	17,2 (13.4-20.6)	10,8 (9.2-13.3)	6,5 (5.8-7.6)	5,9 (5.2-6.8)

The shape and size of spores from the scales plasmodia correspond to *Thelohanellos nikolskii* spores from fins. Pathohistological structure of the cysts from scales of common carp that is presented here is almost identical with those described in paper by Moshu and Molnar (1997). Although *Thelohanellos nikolskii* cause changes on scales and fins, clinical manifestation, the age of fish and the period of occurrence are different. In one year old fingerlings location of plasmodia are fin rays, while in two years old and older carps cysts are located on the scales and sporadically on the skin. According to Moshu and Molnar (1997) in older fish –due to advanced calcification of fin rays–the cartilage is less suitable for plasmodium formation than the scales. Since infection was presented in all investigated fish farms, to its prevalence contributed the fact that the infection of the fins was also present in the investigated ponds (Novakov, 2013). Spreading of thelohanellosis was also made possibly by movement of fry between fishponds where this disease was not taken into account. The second important factor is hydrographical connection between fishponds, where water circulation enables transmission of infective agent. Taking into account small distance between fishponds, fish eating birds are also an important factor in disease spreading. Also, the prevalence

and intensity of infection were higher in facilities where stocking densities were higher, and therefore immunity and conditions of fish were weaker.

CONCLUSIONS

Thelohanellosis manifests on fins in one-year-old carp fingerlings during July and August, on scales and sporadically on skin in two-year-old, three-year-old and older categories of pond-cultured common carp during April and May. During investigation, it has been concluded that infection was present in all investigated fishponds. Histopathological changes of plasmodia and spores from scales and fins are very similar. Losses from thelohanellosis on fins can be significant when disease results with drops of fins, while in the case of thelohanellosis on scales direct losses were not determined. Control of thelohanellosis is still based on compliance with basic sanitary-prophylactic measures such as drying of objects, freezing, mechanical cleaning and disinfection with lime.

REFERENCES

- Achmerov A.C. (1955): Ways of the origin of Myxosporidia species of the genus *Thelohanellus* Kudo from Amur wild carp. *Dokl Akad Nauk SSSR* 105:1129-1132 (in Russian)
- Ćirković M., Petrović Z., Jovanović B. (1983): *Thelohanellus* of carp in the territory of Yugoslavia. - Ist International symposium of ichthyoparasitology parasites and parasitic diseases of fish. Č. Budejovice, Book of abstracts, p 38
- Ćirković M., Ćirković D., Lubat V. (1997): Characteristic developmental stages of *Thelochanellus nikolskii* (1979-1996): *Acta veterinaria* Vol. 47, NO. 4 Pp. 221-235.
- Ćirković M., Milošević N., Jovanović M., Jeremić S., Radosavljević V. (2009): The-lohanellosis of the scales in the two-year-old cultured common carp (*Cyprinus carpio*); 14th EAFP International Conference; Prague, Book of abstracts, p 251
- Desser S.S, Molnar K., Weller I. (1983): Ultrastructure of sporogenesis of *The-lohanellus nikolskii* Achmerov, 1955 (Myxozoa: Myxosporea) from the common carp, *Cyprinus carpio*. *J Parasitol* 69:504-518.
- Jeney G. (1979): The occurrence of *Thelohanellus dogieli* Achmerov, 1955 (Myxosporidia) on carp (*Cyprinus carpio*) in fish ponds in Hungary. *Parasitol Hung* 12:19-2.
- Molnar K. (1982): Biology and histopathology of *Thelohanellus nikolskii* Achme-rov, 1955 (Myxosporea, Myxozoa), a protozoan parasite of the common carp (*Cyprinus carpio*). *Z Parasitenkd* 68:269-277.
- Moshu A., Molnar K. (1997): *Thelohanellus* (Myxozoa: Myxosporea) infection of the scales in the European wild carp *Cyprinus carpio carpio*, *Dis Aquat Org*, Vol. 28:115-123.
- Novakov, N. (2013): Fish diseases caused by species *Thelohanellus nikolskii*. Uni-versity of Novi Sad, Doctoral thesis, (in Serbian).
- Wolf K. and Markiw M.E. (1984): Biology contravenes taxonomy in the Myxozoa: new discoveries show alternation of invertebrate and vertebrate hosts. *Science*, 225: 1449-1452.