

FISH HISTOPATHOLOGY - AN ASSESSMENT PROTOCOL TO DETERMINE FISH HEALTH IN POLLUTED WATER IN SOUTH AFRICA

GM Pieterse¹, JC van Dyk¹, MJ Marchand¹, IEJ Barnhoorn² and MS Bornman²

*1. Department of Zoology, University of Johannesburg, P.O. Box 524, Auckland Park,
Johannesburg, 2006, South Africa*

*2. Department of Urology and Andrology, University of Pretoria, P.O. Box 667,
Pretoria, 0001, South Africa*

HISTOPATOLOGIJA RIBA – PROTOKOL ZA PROCENU ZDRAVSTVENOG STANJA U ZAGAĐENOJ VODI U JUŽNOJ AFRICI

Abstrakt

U procesu biomonitoringa efekata zagađenja vodenih ekosistema Južne Afrike na zdravlje riba, koristili smo histološki protokol za kvalitativnu i kvantitativnu procenu efekata. Cilj istraživanja bila je ocena stepena zagađenosti korišćenjem protokola za procenu zdravstvenog stanja riba koji su bazirani na histologiji, na Mozambičku tilapiju, *Oreochromis mossambicus* i Afričkog soma, *Clarias gariepinus*. Rezultati su poređeni a sa referentnom grupom, koja je gajena u laboratoriji u kontrolisanim uslovima. Primena protokola je uključivala i kvantitavni indeks zdravstvene procene (HAI) za brzu procenu stanja riba na terenu, kao i kvalitativne i kvantitativne histološke procene škrge, jetre i gonada.

Ključne reči: *zdravstveno stanje, histologija, histopatologija, toksikologija, kvalitet vode*

INTRODUCTION

The primary goal of environmental conservation and management of ecosystems is to prevent adverse biological and ecological effects caused by pollution. Therefore an urgent need has arisen for sensitive bio-monitoring tools to indicate the effect of pollution on fish health in aquatic ecosystems (H i n t o n et al., 1992). Histopathological assessment of fish tissue allows for early warning signs of disease and detection of long term injury in cells, tissues or organs. Various biochemical and biological studies of fish have

been used to assess the consequences of environmental toxicants on fish, but histology is able to enhance and add quality to the research carried out by describing cellular changes (V a n D y k et al., 2007) and to quantify the results (B e r n e t et al., 1999; M a r c h a n d et al., 2009). Lower level responses such as the prevalence of histopathological symptoms in fish is indicative of the general quality of the environment and can be related to contamination levels of pollutants such as heavy metals, PAHs, PCBs and DDT. These pollutants induce pathological changes in fish. The histological assessment of fish tissue has relevance as a bio-assessment tool and serves as a method to determine preserved biochemical and physiological changes, caused by pollutants as they occur *in situ* (S h o r t and M e y e r s, 2001). Although (DDT) was banned internationally, it is still used for Malaria vector control in areas of South Africa in accordance with the Stockholm convention. This protocol was applied in an area in Limpopo Province, South Africa where ongoing DDT (1,1,1-trichloro-2,2-bis(4-chlorophenyl) ethane) spraying occurs. The aim of the study was to qualitatively and quantitatively describe the toxic induced histological changes in the selected organs (liver, gills and gonads) of two Southern Africa freshwater fish species, the sharptooth *Clarias gariepinus* and Mozambique tilapia *Oreochromis mossambicus* by applying the Histology-based fish health (HBFH) assessment protocol as a bio-assessment tool in an area where ongoing DDT-spraying occurs.

MATERIALS AND METHODS

Study area

The study areas concerned are situated within the Limpopo Province and are part of the Luvuvhu Catchment that forms part of the larger Limpopo system, which runs downstream into Mozambique. Both species were sampled at a reference site, Albasini dam (AD), (outside the DDT-sprayed area) and at an exposed site, Xikundu weir (XW), in the same river ± 70 km within the DDT-sprayed area, Limpopo Province, South Africa.

Sampling methods

Gill nets were used to acquire a sample size of ten male fish per site for each species. Sampling was carried out in summer during a high flow season after rains (surveys 2-4).

A quantitative health assessment index (A d a m s et al., 1993) was used for rapid evaluation of fish condition in the field. Histological changes of the liver, gills and gonads were described (qualitative) and graded (quantitative) according to the protocol B e r n e t et al. (1999). The protocol has been applied in laboratory and field studies on two Southern Africa freshwater fish species, *C. gariepinus* and *O. mossambicus*.

The histologically prepared microscope slides (H u m a s o n, 1979) of all tissue were studied using light microscopy for the identification of histopathological alterations. The adapted version of the quantitative histological assessment protocol described by B e r n e t et al. (1999) was used to quantify histopathological alterations observed in the selected target organs. A sixth reaction pattern was added to include the occurrence of intersex, considered an irreversible alteration to normal gonadal tissue.

A reference group of *C. gariepinus* (n=20) and *O. mossambicus* (n=20) were bred and kept until sexually mature in an environmental room in reconstituted reverse osmosis water to minimise exposure to toxicants (V a n D y k, 2006) and the same protocol as described above has been applied.

RESULTS

Health Assessment Index (HAI)

The external examination of all species showed that all fish were in a state of good health in terms of the condition of the fins, eyes, mouth, scales, opercula as well as the general appearance. The external appearance showed structural abnormalities in a number of liver including darkening, discoloration and fat spots. Few external and internal parasitic infections were visible in both species from all the sampling sites. The results of the HAI for the two fish species *C. gariepinus* and *O. mossambicus* for the sampling trips in survey 2, survey 3 and survey 4 for the reference site (AD) as well as for the two DDT sprayed areas (ND and XW) are given in Figure 1.

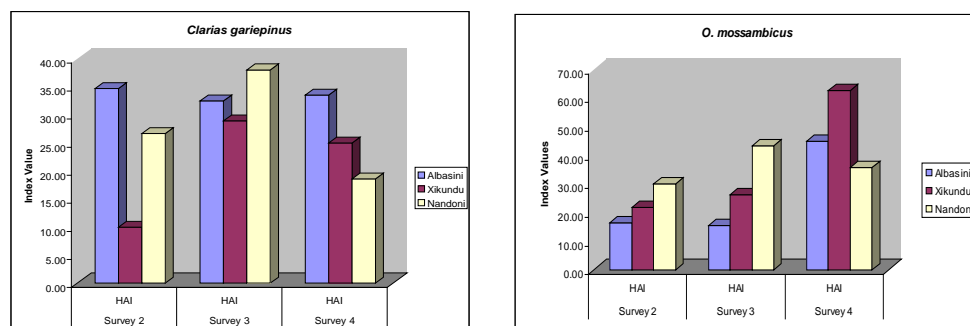


Figure 1. HAI for all sampling periods for *O. mossambicus* and *C. gariepinus*

Cellular and Histopathological Indicators

Qualitative Histological Assessment

All 93 specimens of both *C. gariepinus* and *O. mossambicus* were histologically assessed. This sample size allowed thorough histological assessment of the gills, liver and gonads. The following section reports on the histological observations noted for each organ.

Gill alterations

The following histological alterations were observed: circulatory disturbances including telangiectasia and oedema of secondary lamellae; structural alterations in the form of fusion and branching of primary and secondary lamellae; and plasma alterations with the presence of vacuolation; hyperplasia of the epithelium and infiltration of leucocytes. During the assessment, hyperplasia in the gills of *C. gariepinus* was noted in 16 specimens from AD during survey 3 and intercellular deposits were noted in 21 specimens of *O. mossambicus* in XW from survey 2. These structural alterations frequently observed include epithelial lifting and hyperplasia of the secondary lamellae.

Liver alterations

The following histological alterations were observed: Cord disarray; plasma alterations including granular degeneration of hepatocytes and inter/intra cellular deposits as well fatty degeneration; an increase in the presence of melanomacrophage centers; nuclear alterations; necrosis of hepatic tissue; hypertrophy of hepatocytes, an increase in

connective tissue surrounding central veins, infiltration of mononuclear leukocytes and alterations to the bile ducts including wall proliferation, structural alterations, granular degeneration and nuclear alterations.

Gonad alterations

Ovaries

The alterations that were observed in the ovaries of both species were melanomacrophage centres (MMC) and infiltration of leucocytes in both species.

Testes

Detachment of the basal membrane was observed in *C. gariepinus* from all sampling sites during survey 3, and in AD during survey 4. Interstitial deposits were observed in *C. gariepinus* in AD, ND and in XW during survey 4 and also in AD and XW during survey 2 and 3. Vacuolation was observed AD (survey 3) and XW (survey 4). No cases of intersex were noted in the testes of *C. gariepinus* but in *O. mossambicus* intersex were present at all sampling sites

Quantitative Histological Assessment

During the assessment, certain histological alterations were identified in the selected target organs. Figure 2 presents the Organ Index Values (I_{org}) for both *O. mossambicus* and *C. gariepinus* for the three sampling surveys. The I_{org} values represent the extent of damage to an organ and allows for the comparison of the extent of damage of the same organ in different individuals. The I_{org} means obtained for *O. mossambicus* was also higher than the values obtained for *C. gariepinus*. The I_{org} values in both species were higher in the testes than in the ovaries.

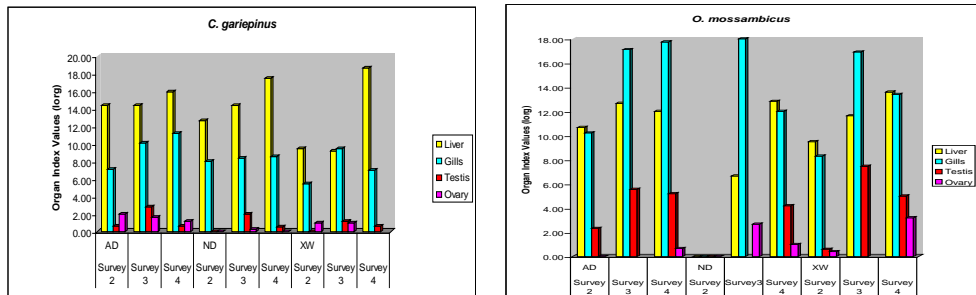


Figure 2: Organ Index (I_{org}) means for the liver, gills, testes and ovaries for *C. gariepinus* and *O. mossambicus*.

The Total Organ Index (Tot-I) means which determines the cumulative degree of damage to all the organs assessed were compared between fish from the three sampling sites, namely AD, ND and XW. The results are presented in Figure 3. In *C. gariepinus*, the highest Tot-I means were recorded during survey 4 for all the sampling sites. The highest Tot-I values for *O. mossambicus* were recorded in survey 3 in XW. In *O. mossambicus* the reference site AD had the lowest Tot-I values.

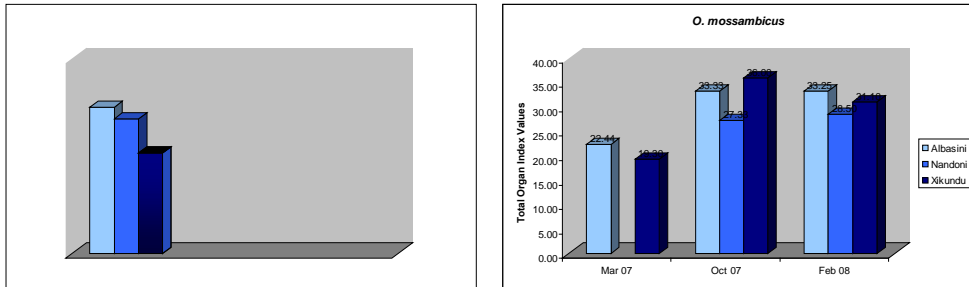


Figure 3: The Total Organ Index (Tot-I) values for *C. gariepinus* and *O. mossambicus* in the AD, ND and XW.

DISCUSSION

Adams et al. (1993) developed a systematic fish health/condition or necropsy-based procedure for use by fisheries personnel at field level. It was developed to use minimal equipment to provide rapid, relatively inexpensive method in order to detect trends in health and condition of fish populations. This method provides a systematic method for documenting lesions and to compare incidences of gross-observable lesions between sites.

Index variables are assigned numerical values based on the degree of severity or damage incurred by an organ or tissue from environmental stressors. Figure 1 shows that high and low index means were obtained for *C. gariepinus* in the reference site (AD) and low index values for the reference site in *O. mossambicus*. According to Adams et al. (1993), the HAI index was successfully applied by the Tennessee Valley Authority (TVA). The range of reservoir HAI values was 17 (best) for a relatively pristine system, to 79 (worst) for a river that receives contaminants from numerous sources, the most notable being a river into which effluents from a pulp and paper plant were discharged. The HAI has also been applied to assess the effects on fish health exposed to polychlorinated biphenyls (PCBs) in Hartwell reservoir (Adams et al., 1993). The reference site HAI value was 42, while the most contaminated site had an HAI value of 74. HAI values for Pigeon River receiving pulp and paper effluents ranged from 21 (reference site) to 60 (contaminated site) (Adams et al., 1993). These results confirm that fish exposed to toxicants have a higher HAI score indicating more alterations and poorer fish health. The results indicate that all the fish were in good health.

Histopathology allows the examination of organs from fish of any size, age or type to be examined. Sectioning of these fixed tissues allowed retention of *in vivo* relationships. This often allows for diagnoses of changes observed grossly as well as indications of mechanisms of toxicity (Marchand et al., 2009). Macroscopic signs of toxicity are almost always preceded by changes at the tissue, cellular or molecular levels (Senger and Brunbeck 1990). When cell injury or death of cells without death of the organisms occurs, this is followed by cellular reactions and / or host responses that can be described and sometimes be diagnostic of cause (Hinton et al., 1992).

All target organs were assessed in terms of a quantitative histological assessment protocol. During the assessment, certain histological alterations were identified in the selected target organs. The results showed that in both species the gills and liver were

more affected than the gonads (testes and ovaries). *O. mossambicus* were also more affected (showing higher Tot-I values). *O. mossambicus* showed higher Index values for the gonads, which could be due to the occurrence of intersex in the testes in all the sampling sites. Barnhoorn et al. (2004) observed intersex in feral sharptooth catfish from estrogen polluted water. Intersex was not observed in the testes of *C. gariepinus*.

CONCLUSION

Fish histology was used as a tool to monitor the health status in an area where ongoing DDT spraying occurs by implementing qualitative and quantitative histological assessment methods. The results obtained from the reference site (AD) showed that fish are equally affected and that DDT might not be the causative agent.

Based on the HAI, the fish from surveys 2, 3 and 4 in all three sampling sites were in a state of good health. Histopathological alterations of *C. gariepinus* and *O. mossambicus* were identified in the gills, liver and gonads. All the values were higher than the values obtained for a reference group for both species that were bred in toxicant free water (Van Dyk, 2006). Histopathological alterations in fish tissue can be used as a tool to monitor the health status of ecosystems as they provide a more comprehensive knowledge of the effects of toxicants on fish health. Histopathology gives an indication of the serious effects of toxicants, known to be in the water, on fish health. There was no proof that fish from ND and XW was more severely affected than AD. It should be noted that intersex was present in the testes of *O. mossambicus* during all surveys in ND, XW and AD. However, the analysis of the Tot-I from the quantitative histological assessment did not provide outright evidence that ND and XW was in a more severe state than AD, based on overall histopathological alterations in fish tissue.

Acknowledgements:

The financial support by the Water Research Commission (WRC, K5/1674) to Prof MS Bornman and the National Research Foundation (GUN, 61881) of South Africa is hereby acknowledged.

REFERENCES

- Adams, S. M., Brown, A. M. and Goede, R. W. (1993). A quantitative health assessment index for rapid evaluation of fish condition in the field. *T. Am. Fish. Soc.*, 122, 63-73.
- Barnhoorn, I. E. J., Bornman, M. S., Pieterse, G. M. and Van Vuren, J. H. J. (2004). Histological evidence of intersex in feral sharptooth catfish (*Clarias gariepinus*) from an estrogen-polluted water source in Gauteng, South Africa. *Environ. Toxicol.* 19, 603-608.
- Bernet, D., Schmidt, H., Meier, W., Berkhardt-Holm, P. and Wahli, T. (1999). Histopathology in fish: proposal for a protocol to assess aquatic pollution. *J. Fish Dis.* 22, 25-34.
- Hinton, D. E., Baumann, P. C., Gardner, G., Hawkins, W. E., Hendricks, J. D., Murchelano, R. A. and Okihira, M. S. (1992). Histopathological biomarkers. In *Biomarkers: biochemical, physiological, and histological markers of anthropogenic stress*. Ed-

ited by Huggett, R. J., Kimerle, R. A., Mehrle, P. M. (Jr) and Bergman, H. L. United States of America: Lewis Publishers.

Humason, G. L. (1979). Animal tissue techniques. 4th Ed. W.H. Freeman, New York.

Marchand, M. J., Pieterse, G. M. and Barnhoorn, I. E. J. (2009). Histopathological alterations in the liver of the sharptooth catfish *Clarias gariepinus* from polluted aquatic systems in South Africa. Environ. Toxicol. 24, 133-147.

Segner, H. and Braunbeck, T. (1990). Adaptive changes of liver composition and structure in golden ide during winter acclimatization. J. Exp. Zool. 255, 171-185.

Short, S. and Meyers, T. R. (2001). Histology in Finfish. NWFHS Laboratory Procedures Manual. Version 1.0. Alaska Fish and Game C.F. Division.

Van Dyk, J. C., Pieterse, G. M. and Van Vuren, J. H. J. (2007). Histological changes in the liver of *Oreochromis mossambicus* (Cichlidae) after exposure to cadmium and zinc. Ecotox. Environ Safe. 66, 432-440.

Van Dyk, J. C. (2006). A qualitative and quantitative assessment of the normal histology of selected target organs of *Clarias gariepinus* and *Oreochromis mossambicus*. Unpublished Ph.D Thesis, University of Johannesburg, Johannesburg.