

## **SPHAEROSPORA MOLNARI (MYXOZOA) IN COMMON CARP FINGERLINGS**

NIKOLINA NOVAKOV<sup>1</sup>, MIROSLAV ĆIRKOVIĆ<sup>2</sup>, DRAGANA LJUBOJEVIĆ<sup>2</sup>,  
BOJAN ADŽIĆ<sup>3</sup>, PELIĆ MILOŠ<sup>2</sup>, BILJANA BOŽIĆ<sup>2</sup>, JELENA BABIĆ<sup>2</sup>, DALIBOR  
TODOROVIĆ<sup>2</sup>

<sup>1</sup>University of Novi Sad, Faculty of Agriculture, Trg Dositeja Obradovića 8, 21000 Novi Sad, Serbia, e-mail: milosevicnina@gmail.com

<sup>2</sup>Scientific Veterinary Institute „Novi Sad“, Rumenački put 20, 21000 Novi Sad, Serbia,

<sup>3</sup>Veterinary diagnostic laboratory, Podgorica, Montenegro

### **SPHAEROSPORA MOLNARI (MYXOZOA) KOD ŠARANSKE MLAĐI**

#### *Apstrakt*

Sferosporidioza škrge je obolenje riba izazvano parazitom *Sphaerospora molnari* koji napada škrge i kožu. Prvo pojavljivanje sferosporidioze škrge kod šaranskih mladunaca utvrđeno je u Mađarskoj još 1972, zatim u Češkoj i Poljskoj, dok je kod nas obolenje prisutno od sredine osamdesetih godina prošlog veka. Molnar, koji je prvi je izučavao patogeni efekat ovog uzročnika, najpre ga je identifikovao kao *Sphaerospora carassi*. Češki istraživači Lom *et* Dycova detektovali su uzročnika sferosporidioze škrge iz škržnog materijala obolelih mladunaca šarana pomoću histološke sekcije tkiva i predložili da se parazitu da ime *Sphaerospora molnari*. Ovo obolenje je dosta često kod mladunaca ribnjačkog šarana i amura, pri čemu intenzitet infestacije može dostići čak i do 100%. Cilj ovog rada jeste da se utvrdi prisustvo obolenja izazvanog parazitom *Sphaerospora molnari* i da se isprate kliničke i patohistološke promene kod infestiranih mladunaca šarana. Istraživanja su sprovedena na 18 šaranskih ribnjaka u Srbiji, od 2008. do 2012. godine, a u sklopu sistemskog monitoringa najznačajnijih protozooza šarana. Mladunci šarana pregledani su tokom čitavog vegetacionog perioda. Praćene su kliničke promene, i uzimani su uzorci za nativnu mikroskopiju koja je rađena pomoću svetlosnog mikroskopa. Od inficiranih jedinki uzimana je tkivo škrge za patohistološku analizu koja je sprovedena klasičnom metodologijom, fiksiranjem u 10% formalinu, sečenjem 5 µm velikih isečaka koji su kalupljeni u parafin i bojenjem isečaka pomoću H&E. Prisustvo *S. molnari* ustanovljeno je kod mladunaca šarana od 20 dana do 3 meseca starosti. Na škrgrama su bili prisutni razvojni stadijumi i zrele spore što se moglo uočiti na stratifikovanom epitelu škržnih filamenata. Spore su invadirale epitel i formirale velike klustere. Akumulacija razvojnih stadijuma i zrelih spora bila je

prisutna je i kod dvostrukog sloja epitelnih ćelija koje pokrivaju sekundarne lamele, i to najčešće između unutrašnjeg i spoljašnjeg omotača izazivajući tako distenziju tkiva. Zaražene lamele podležu nekrozi, što dovodi do kretanja spora prema spolja. Veličina spora iznosila je 10 x 10 µm. Klinički, obolenje se manifestovalo pojavom beličastih depozita na škragama kao posledica agregacije parazita na njima, pri čemu paraziti mogu da zauzmu i do 80% površine slojevitog epitela, prekrivajući pločice i lukove škrge. Pritisak parazita koji se razmnožavaju je takav da vrši ćelijsku deformaciju tkiva i na kraju se uočava istančanost citoplazme ćelija šktznog epitela u obliku mreže. Pošto spore prekrivaju najveći deo respiratornog epitela, smanjuju otpornost organizma i stvaraju uslove za razvoj drugih uzročnika obolenja (prvenstveno trematoda), što *Sphaerosporu molnari* svrstava u patogene parazite. Lokalizacija, veličina spora odnosno razvojnih stadijuma *S. molnari*, kao i kliničke i patohistološke promene zabeležene tokom ovog istraživanja odgovaraju rezultatima koje su opisali ostali istraživači koji su se bavili ovom problematikom. Pošto ne postoji ni jedno adekvatno terapijsko sredstvo, kontrola sferosporidioze i dalje se bazira na pridržavanju osnovnih sanitarno–profilaktičkih mera, kao što su isušivanje objekata, izmrzavanje, mehanička obrada tla i dezinfekcija krečom.

*Ključne reči:* *Sphaerospora molnari*, škrge, mladunci šarana

*Keywords:* *Sphaerospora molnari*, gills, young carps

## INTRODUCTION

Sphaerosporosis of the gills is a disease of young carps caused by *Sphaerospora molnari* (Lom et al., 1983). The first severe outbreak of sphaerosporosis of the gills in young carps was described by Hungarian researchers Hámory and Molnar (1972). Molnar (1979) studied the pathogenic effects of this causative agent which he named *Sphaerospora carassii*. Later, the same author claimed that sphaerosporosis of the gills, at least in mirror carp, may result in changes in superficial layers of the skin in about 50% of infected fish. Lom et Dycova (1980) detected the causative agent of gill sphaerosporosis in samples of diseased young carps and suggested the name *Sphaerospora molnari*. In Serbia, sphaerosporidiosis of the gills has been present in carp fish ponds since the 1980s (Ćirković, 1986; Ćirković and Novakov, 2013). In the gills, *S. molnari* invades stratified epithelium of gill filaments and secondary lamellae causing branchial lesions and must be regarded as a serious pathogen of yearling carp. Specific therapeutic measures are not known. The present study deals with the occurrence of *Sphaerospora molnari* and with health problems of young carps affected in pond cultures.

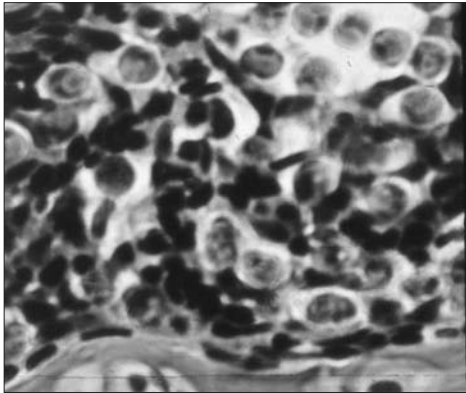
## MATERIALS AND METHODS

Investigation was carried out in the northern Serbia (Vojvodina province) in 18 fish ponds, until 2008 to 2014, during a systematic survey of protozoan parasites of carp. Common carp *Cyprinus carpio* L. fingerlings were examined during the whole growing season. All investigated fish ponds were traditional soil ponds which provide water from channel network, rivers Tisa, Tamiš, and Danube, and wells. After clinical observations of fish parasitological examination were performed from gill samples using light microscopy. Spores

were studied fresh. Samples of infected gills were fixed in 10% neutral formalin and processed, sliced to 5- $\mu\text{m}$ -thick paraffin-wax embedded tissue sections, mounted and stained in haematoxylin and eosine.

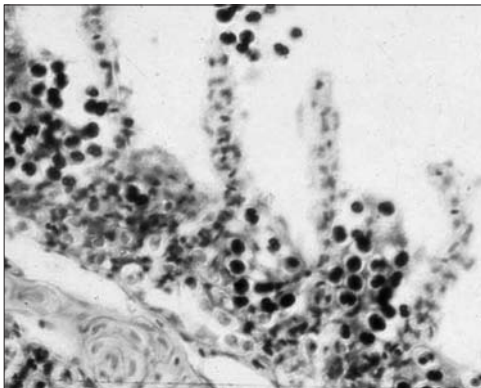
## RESULTS AND DISCUSION

*Sphaerospora molnari* parasites were present in young fish at the age of 20 days to 3 months. The development stages and mature spores of *S. molnari* were detected on the epithelium of the gill filaments (Figure 1). They pervaded epithelium diffusely or formed large clusters. In the case of massive infection the parasites may completely destroy the interlamellar cell layer. The accumulation of development stages and mature spores were also present in the double layer epithelium, which cover the secondary lamellae, often between the inner and outer layer, leading to the distension of the tissue (Figure 2). The infected lamellae undergo necrosis, which results in the release of the spores. Size of the spores is 10 x 10  $\mu\text{m}$ .



**Figure 1.** *Sphaerospora molnari* in gill tissue, H&E

Clinically, disease was observed on the gills in the form of whitish deposits as a result of parasites aggregation on them, where spores can take up to 80% of the stratified epithelium covering the gill arches and tiles. Since parasites are covered most of the respiratory epithelium, they reduce resistance and create conditions for the development of other causes of diseases.



**Figure 2.** Spores of *Sphaerospora molnari* in gill, H&E

*Sphaerospora molnari* identified during this investigation is a parasite of carp which is the most present in Hungary, Czech Republic and Poland, and it is a typical myxosporean in intensive aquaculture (Antychowicz, 1985; Dycová and Lom, 1988; Lom and Dycová, 1992; El-Matbouli et al., 1992; Yoney and Yoney, 1995; Pojmanska et al., 1998).

Localisation and size of individual developmental forms of *Sphaerospora molnari* was generally the same, as described in the literature (Molnar, 1979; Lom et al., 1983; Antychowicz, 1985; Dycová and Lom, 1988; Lom and Dycová, 1992; El-Matbouli et al., 1992).

Covering the majority of the respiratory epithelium, the spores weaken the host immunity and make conditions for the development of other pathogens. Thus, *Sphaerospora molnari* (Molnar, 1979) is rather pathogenic parasite. This is supported by the fact that spores are usually detected in fish invaded with large numbers of dactylogyres.

## CONCLUSIONS

Gill sphaerosporosis manifests on gills in 20 days to 3 months old common carp fingerlings from fish ponds of Serbia. The most prominent clinical signs of the disease were present of whitish deposits on gills as a result of parasites aggregation on them and the consequently difficulty in breathing. Histological analysis of gill confirms the presence of development stages and mature spores of *S. molnari*. Since *S. molnari* invades stratified epithelium of gill filaments and secondary lamellae causing branchial lesions this parasite must be regarded as a serious pathogen of yearling carp, especially when it occurs together with other pathogens. Control of gill sphaerosporosis is still based on compliance with basic sanitary-prophylactic measures such as drying of objects, freezing, mechanical cleaning and disinfection with lime.

## REFERENCES

- Antychowicz, J. (1985): Sferosporoza skrzeli i skory karpi (Sphaerosporosis of carp gills and skin). *Med. Wet.* 41, 4: 216-220.
- Ćirković, M. (1986): Myxosporidiosis of the common carp fingerlings. Doctoral thesis, Veterinary Faculty, Beograd (in Serbian)
- Ćirković, M., Novakov, N. (2013): Parasitic diseases of cyprinid fishes. Scientific Veterinary Institute "Novi Sad", 229 pp.
- Dycova, I., Lom, J. (1988): Review of pathogenic myxosporeans in the intensive culture of carp (*Cyprinus carpio*) in Europe. *Folia Zoologica*, 35: 289-307.
- El-Matbouli, M., Fisher-Scherl, T., Hoffmann, W. (1995): Present knowledge of the life cycle, taxonomy, pathology, and therapy of some Myxosporea spp important for freshwater fish. *Ann. Rev. Fish Diseases*, 2: 367-402.
- Hamory, G., Molnar, K. (1972): Egzsejtu parayitak okoyta ivadekbetegsegek togyadasa-kogban. *Magyar Allotorvosok Lapja*, 27: 258-60.
- Lom, J., Dycova, I. (1980): Myxosporidozy a razvoj rybničniprodukce kapra. *Veterinarstvi*, 30: 176-7.
- Lom, J., Dycova, I. (1992): Protozoan parasites of fishes. Elsevier, Amsterdam.
- Lom, J., Dycova, I., Pavlaskova, M., Grupcheva, G. (1983): *Sphaerospora molnari* sp. nov. (Myxozoa: Myxosporea), an agent of gill, skin and blood sphaerosporosis of common carp in Europe. *Parasitology*, 86: 529-535.

Molnar, K. (1979): Gill sphaerosporosis in the common carp and grass carp. *Acta Veterinaria Academiae Scientiarum Hungaricae*, 27: 99-113.

Pojmanska, T., Wlasow, T., Gomulka, P. (1998): *Sphaerospora renicola* and *Sphaerospora molnari* in Poland and spring sphaerosporosis of carp. *Acta Ichthyologica et Piscatoria*, 28: 25-31.

Yeney, Z., Yeney, G. (1995): Recent achievements in studies on diseases of common carp (*Cyprinus carpio* L.). *Aquaculture*, 129: 297-420.